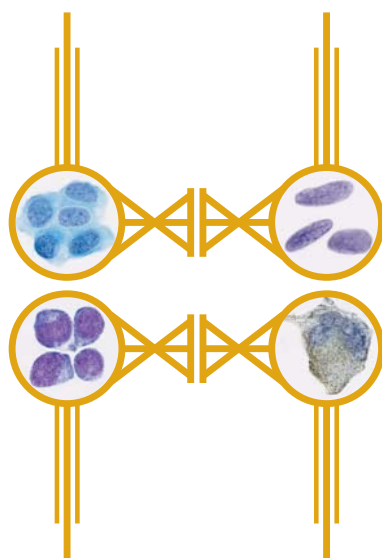


PRACTICAL PRINCIPLES OF CYTOPATHOLOGY
REVISED EDITION

To Alexander, David, and Jacqueline
Love, Dad

PRACTICAL PRINCIPLES OF CYTOPATHOLOGY

REVISED EDITION



Richard M. DeMay, MD
Professor of Pathology
Director of Cytopathology
University of Chicago



American Society for
Clinical Pathology
Press
Chicago, IL

Publishing Team

Jeffrey Carlson (design)

Erik Tanck (production)

Joshua Weikersheimer (publishing direction)

Author's Acknowledgments

Thanks to the outstanding staff of the section of cytopathology: Ann Marie Maslan, Patsy Lin, Sean Macleish, Namrta Rodriguez, Rebecca Danahey, Raephaele Masirnille, Jeffrey Mueller, and Ward Reeves. Thanks also to Tom Stricker for helpful suggestions on revisions. And of course, Joan Hives and Joshua Weikersheimer—they're still the best!

Notice

Trade names for equipment and supplies described herein are included as suggestions only. In no way does their inclusion constitute an endorsement or preference by the American Society for Clinical Pathology. The ASCP did not test the equipment, supplies, or procedures and therefore urges all readers to read and follow all manufacturers' instructions and package insert warnings concerning the proper and safe use of products.



Copyright © 2007 by the American Society for Clinical Pathology.
All rights reserved. No part of this publication may be reproduced, stored in a retrieval system, or transmitted in any form or by any means, electronic, mechanical, photocopying, recording, or otherwise, without the prior written permission of the publisher.

11 10 09 08 07 5 4 3 2 1

Printed in Singapore.

Table of Contents

Preface xi

ONE

The Pap Test 1

- 1.1 Squamous Epithelium 1
- 1.2 Benign Proliferative Reactions 3
- 1.3 Dysplasia and Carcinoma In Situ 4
- 1.4 Microinvasive Carcinoma 8
- 1.5 Squamous Cell Carcinoma 9
- 1.6 Cervical Cancer: Further Considerations 11
- 1.7 Atypical Squamous Cells 13
- 1.8 Benign Cellular Changes 14
- 1.9 Glandular Epithelium 18
- 1.10 Rare Tumors 22
- 1.11 Pregnancy-Associated Changes 23
- 1.12 Miscellaneous Findings 23
- 1.13 Summary and Conclusions 24

TWO

The Respiratory Tract 27

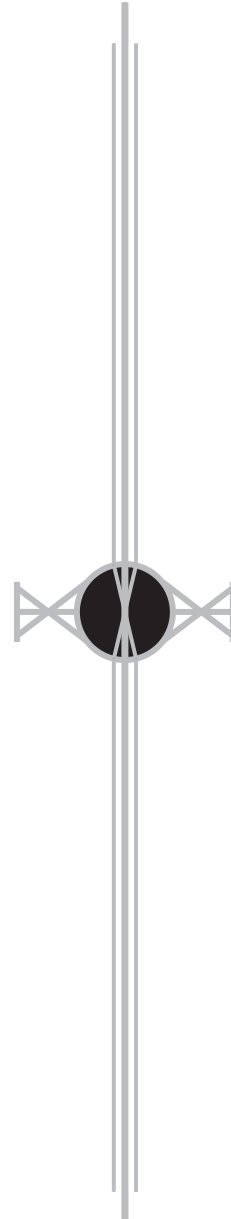
- 2.1 Diagnostic Respiratory Cytology 27
- 2.2 The Cells 28
- 2.3 Benign Proliferation 32
- 2.4 Therapeutic Agents 34
- 2.5 Granulomatous Inflammation 35
- 2.6 Specific Infections 36
- 2.7 Pulmonary Embolism/Infarct 37
- 2.8 Miscellaneous Benign Diseases 37
- 2.9 Malignant Diseases 38

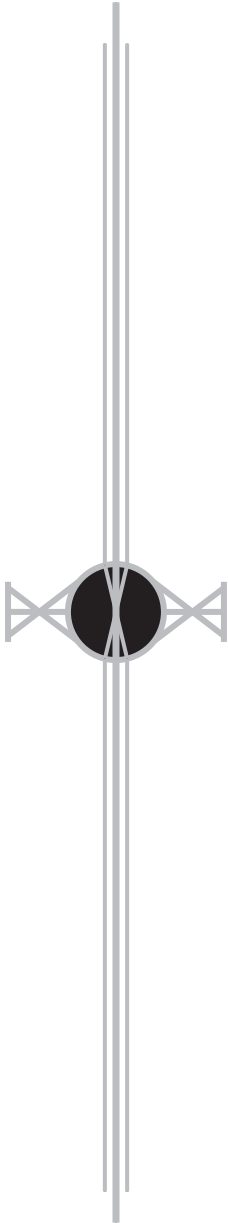
THREE

Fluids 49

BODY CAVITY FLUIDS 49

- 3.1 Pleural Effusions 49
- 3.2 Ascites 49
- 3.3 Pericardial Effusions 50
- 3.4 Special Types of Effusions 50
- 3.5 The Cells 51
- 3.6 Specific Benign Effusions 54





- 3.7 Malignant Effusions 55
- 3.8 Mesothelioma 62
 - BODY CAVITY WASHINGS 64**
- 3.9 Mesothelial Cells 64
- 3.10 Gynecologic Cytology in Peritoneal Washes 64
 - SYNOVIAL FLUID 66**
- 3.11 The Cells 66
- 3.12 Diseases of Synovium and Joints 67
 - NIPPLE DISCHARGE 69**
- 3.13 The Cells 69
- 3.14 Cytology of Abnormal Nipple Discharge 70
- 3.15 Breast Cancer 71

FOUR

The Gastrointestinal Tract 73

- ORAL CAVITY 73**
- 4.1 The Cells 73
- 4.2 Benign Diseases 74
- 4.3 Malignant Diseases 75
 - ESOPHAGUS 76**
- 4.4 The Cells 76
- 4.5 Benign Diseases 76
- 4.6 Malignant Diseases 79
 - STOMACH 81**
- 4.7 The Cells 81
- 4.8 Benign Diseases 82
- 4.9 Malignant Diseases 84
 - SMALL INTESTINE 87**
- 4.10 The Cells 87
- 4.11 Infections 88
- 4.12 Malignant Diseases 88
 - COLON AND RECTUM 89**
- 4.13 The Cells 89
- 4.14 Benign Diseases 90
- 4.15 Malignant Diseases 91
 - EXTRAHEPATIC BILIARY TRACT 92**
- 4.16 The Cells 92
- 4.17 Benign Tumors 93
- 4.18 Malignant Tumors 93

FIVE**Urine 95**

- 5.1 Urinary Tract Cytology **95**
- 5.2 The Cells **96**
- 5.3 Basic Specimens **99**
- 5.4 Benign Diseases of the Urinary Tract **99**
- 5.5 Renal Transplant **102**
- 5.6 Cellular Reaction to Therapeutic Agents **103**
- 5.7 Urinary Tract Cancer **104**

SIX**Cerebrospinal Fluid 115**

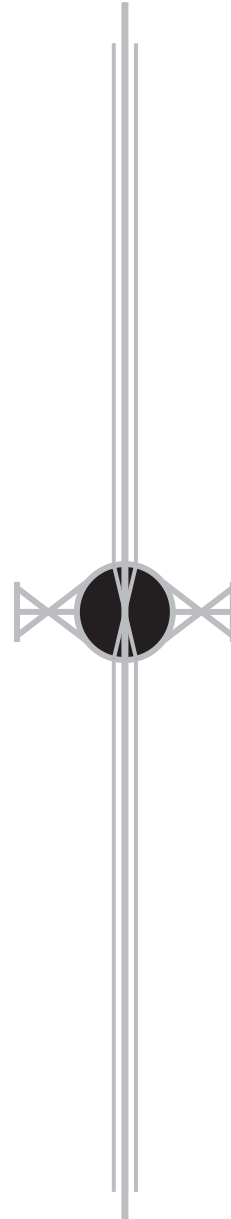
- 6.1 CSF Physiology **115**
- 6.2 CSF Cytology **115**
- 6.3 Reactive Conditions: Hemorrhage, Inflammation, Infection **119**
- 6.4 Central Nervous System Tumors **121**
- 6.5 Primary Tumors of the Central Nervous System **121**
- 6.6 Metastatic Malignancy **127**

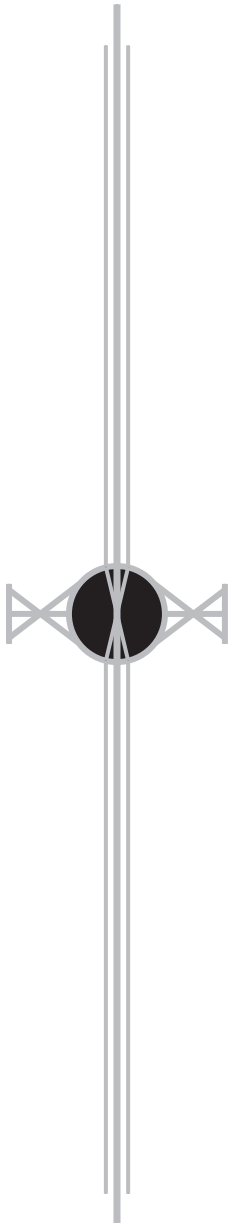
SEVEN**Fine Needle Aspiration Biopsy 131**

- 7.1 Advantages **131**
- 7.2 Complications **132**
- 7.3 Contraindications **134**
- 7.4 Performing, Interpreting, and Reporting the Biopsy **134**

EIGHT**The Gut Course 139**

- 8.1 Tumor Classification **139**
- 8.2 The Building Blocks of Cytodiagnosis **140**
- 8.3 Squamous Cells **141**
- 8.4 Glandular Cells **142**
- 8.5 Leukocytes **147**
- 8.6 Giant Cells **152**
- 8.7 Small Cells **153**
- 8.8 Spindle Cells **155**
- 8.9 Clear Cells **155**
- 8.10 Granular Cells **156**
- 8.11 Neuroendocrine Cells **157**
- 8.12 Melanoma **159**
- 8.13 Background/Extracellular Material **161**



**NINE****Soft Tissue Tumors 163**

- 9.1 FNA Biopsy of Soft Tissue Tumors **165**
- 9.2 Spindle Cell Tumors **167**
- 9.3 Round Cell Tumors **171**
- 9.4 Pleomorphic Tumors **172**
- 9.5 Myxoid Tumors **174**
- 9.6 Biphasic Tumors **175**

TEN**Head and Neck 179**

- 10.1 Cervical Cysts **179**
- 10.2 Head and Neck Neoplasms **181**
- 10.3 Parathyroid **182**

ELEVEN**Salivary Glands 187**

- 11.1 Normal Salivary Glands **187**
- 11.2 Salivary Gland Diseases **189**
- 11.3 Salivary Gland Neoplasms **193**
- 11.4 Salivary Gland Masses in Children **203**

TWELVE**Thyroid 205**

- 12.1 Fine Needle Aspiration Biopsy: The Best Test **205**
- 12.2 The Normal Thyroid Gland **206**
- 12.3 Diseases of the Thyroid **208**
- 12.4 Follicular Lesions **210**
- 12.5 Malignancy (Other Than Follicular Carcinoma) **215**
- 12.6 Therapeutic Effects **224**
- 12.7 Dys hormonogenetic Goiter **224**
- 12.8 Pregnancy **225**
- 12.9 Cysts **225**
- 12.10 Hot Nodules and Graves Disease **225**

THIRTEEN**Lymph Nodes 227**

- 13.1 The Cells **227**
- 13.2 Nonneoplastic Diseases of the Lymph Node **232**
- 13.3 Metastatic Malignancy **234**
- 13.4 Malignant Lymphomas **234**
- 13.5 Histiocytic Neoplasms **248**

- 13.6 Hodgkin Lymphoma **249**
- 13.7 Plasma Cell Myeloma **251**
- 13.8 Leukemic Lymphadenopathy **252**
- 13.9 Extramedullary Hematopoiesis (Myeloid Metaplasia) **254**

FOURTEEN

Breast 257

- 14.1 The Triple Test **257**
- 14.2 The Cells **258**
- 14.3 Nonneoplastic Diseases and Conditions of the Breast **259**
- 14.4 Benign Breast Neoplasms **264**
- 14.5 Malignant Breast Neoplasms **267**
- 14.6 Male Breast **278**

FIFTEEN

Thorax 281

LUNG 281

- 15.1 Transbronchial (Wang) Needle Biopsy **281**
- 15.2 The Cells **282**
- 15.3 Benign Diseases of the Lung **282**
- 15.4 Lung Cancer **285**

PLEURA 297

- 15.5 Malignant Mesothelioma **297**

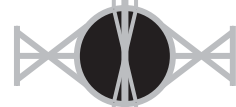MEDIASTINUM 298

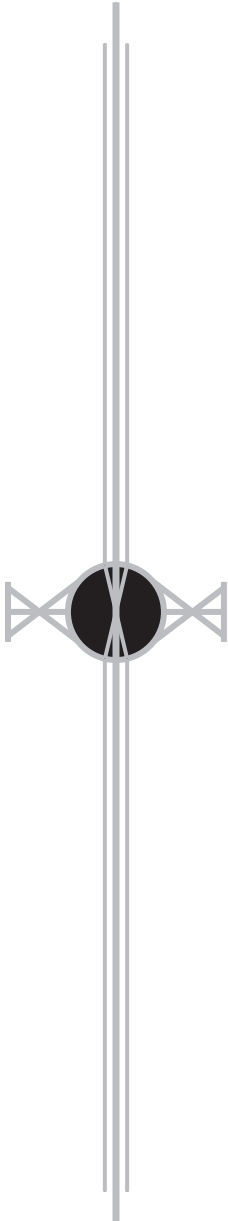
- 15.6 Thymoma **298**
- 15.7 Thymic Carcinoid **300**
- 15.8 Germ Cell Tumors **301**
- 15.9 Malignant Lymphoma **301**
- 15.10 Neurogenic Tumors **302**
- 15.11 Mesenchymal Tumors **305**
- 15.12 Metastases **305**

SIXTEEN

Liver 307

- 16.1 The Cells **307**
- 16.2 Inclusions and Pigments **308**
- 16.3 Diffuse Liver Diseases **309**
- 16.4 Nodular Liver Diseases **310**





SEVENTEEN

Pancreas 323

- 17.1 FNA Biopsy of the Pancreas **323**
- 17.2 The Cells **323**
- 17.3 Diseases of the Pancreas **324**
- 17.4 Ductal Adenocarcinoma **327**
- 17.5 Metastatic Tumors **329**
- 17.6 Neoplastic Cysts **329**
- 17.7 Acinar Cell Carcinoma **333**
- 17.8 Endocrine Neoplasms:
Islet Cell and Carcinoid Tumors **333**

EIGHTEEN

Kidney 337

- 18.1 The Cells **337**
- 18.2 Benign Diseases **338**
- 18.3 Malignant Diseases **340**
- 18.4 Malignant Renal Tumors in Children **347**

NINETEEN

Adrenal Glands 351

- 19.1 Evaluation of Patients With Adrenal Masses **351**
- 19.2 Adrenal Cortex **351**
- 19.3 Adrenal Medulla **355**

TWENTY

Gonads 361

- 20.1 Testis and Male Genital System
(Exclusive of Prostate) **361**
- 20.2 Gonadal Tumors **362**
- 20.3 Ovary and Female Pelvis **367**

TWENTY-ONE

Microbiology 373

- 21.1 Viruses **373**
- 21.2 Bacteria **373**
- 21.3 Fungi **374**
- 21.4 Parasites **376**
- 21.5 Arthropods **378**
- 21.6 Contaminants **378**

Appendix: Liquid-Based Cytology 381

Index 393

Preface

vade mecum *n*: **1**: a portable, practical reference **2**: go with me

Evade, invade, pervade—ever on the go with a prefix to steer us. This book is for those with limited time and immediate information needs. Going against the trend for ever larger information sources in print, this book follows instead the trend from desktop to palmtop.

A *vade mecum* is supposed to be concise and *at hand*: in *Practical Principles of Cytopathology* readers can expect *handy* information. The surgical pathologist needing quick cytomorphologic consult will find it here—and in a form easily carried to a colleague's office. The resident with only a few months' time to master the essentials can fall asleep (when exhaustion strikes) without fear of injury when this book falls!

The Art & Science of Cytopathology is encyclopedic: it comprises synoptic atlases, thousands of references, etc. *Practical Principles of Cytopathology* dispenses with atlases and references, offering instead what the diagnostician needs *at hand*, without urging more going to yet another set of pages. Nonetheless, because cytopathology is a visual art and science, we've built in over 1200 images, each of them *at hand* within a page of the information you are seeking.

Rabbi Hillel was once challenged to teach the whole Torah while his challenger stood on one foot. He replied, "That which is hurtful to you do not do to others. That is the whole of the Torah, now *go study*." We've striven to make *Practical Principles of Cytopathology* a wealth of information for the hand (we can't stop to stand on one foot), but when further study is needed, *The Art & Science of Cytopathology* stands ready.

Mac DeMay

Author

Joshua Weikersheimer

ASCP Press

